

## VIDEOS IN CLINICAL MEDICINE

## Thoracentesis

Todd W. Thomsen, M.D., Jennifer DeLaPena, M.D., and Gary S. Setnik, M.D.

From the Department of Emergency Medicine, Mount Auburn Hospital, Cambridge, MA (T.W.T., G.S.S.); the Department of Emergency Medicine, Beth Israel Deaconess Medical Center, Boston (J.D.); and the Division of Emergency Medicine, Harvard Medical School, Boston (T.W.T., J.D., G.S.S.). Address reprint requests to Dr. Thomsen at the Department of Emergency Medicine, Mount Auburn Hospital, 330 Mount Auburn St., Cambridge, MA 02238, or at tthomsen@mah.harvard.edu.

N Engl J Med 2006;355:e16.  
Copyright © 2006 Massachusetts Medical Society.

**INDICATIONS**

Thoracentesis is a valuable diagnostic procedure in a patient with pleural effusion of unknown causation. Analysis of the pleural fluid will allow its categorization as either a transudate (a product of unbalanced hydrostatic forces) or an exudate (a product of increased capillary permeability or lymphatic obstruction) (Table 1). If the effusion seems to have an obvious source (e.g., in an afebrile patient with congestive heart failure and bilateral pleural effusions), diagnostic thoracentesis may be deferred while the underlying process is treated. The need for the procedure should be reconsidered if there is no appropriate response to therapy.<sup>1</sup>

Thoracentesis, as a therapeutic procedure, may dramatically reduce respiratory distress in patients presenting with large effusions.

**CONTRAINDICATIONS**

There are limited data on the safety of thoracentesis in patients who are using anticoagulant medications or those with coagulopathy or thrombocytopenia. One small study suggests that the procedure is safe and that fresh-frozen plasma is not needed in patients with mild elevations of the prothrombin time or partial-thromboplastin time (<1.5 times the upper limit of the normal range).<sup>2</sup> The decision to use reversal agents in patients with severe coagulopathy or to use platelet transfusions in patients with clinically significant thrombocytopenia must be made on an individual basis.

**Table 1. Common Causes of Transudative and Exudative Pleural Effusions and Criteria for the Differentiation of Transudates and Exudates.\***

Variable	Transudate	Exudate
<b>Common causes</b>	Congestive heart failure Cirrhosis Nephrotic syndrome Pulmonary embolism	Cancer Pneumonia Trauma Tuberculosis Pulmonary embolism Rheumatoid arthritis Systemic lupus erythematosus
<b>Criteria for differentiation</b>		
Ratio of pleural fluid protein to serum protein	<0.5	>0.5
Ratio of pleural fluid LDH to serum LDH	<0.6	>0.6
Pleural fluid LDH	<2/3 upper limit of normal for serum	>2/3 upper limit of normal for serum

\* Data are from Light.<sup>1</sup> LDH denotes lactate dehydrogenase.

Thoracentesis must be performed with extreme care in patients who are receiving mechanical ventilation, because positive-pressure ventilation may bring the lung close to the thoracentesis needle, thus theoretically increasing the risk of tension pneumothorax. Ultrasonography may be beneficial in these situations.

Thoracentesis should be deferred in patients with severe hemodynamic or respiratory compromise until the underlying condition can be stabilized. In patients with small or loculated effusions, the procedure should be performed by an experienced clinician, ideally with ultrasonographic guidance.

The thoracentesis needle should not pass through sites of cutaneous infection (such as cellulitis or herpes zoster) on the chest wall. If such a lesion is present, another entry site should be sought.

#### EQUIPMENT

Numerous prepackaged thoracentesis kits (e.g., Safe-T-Centesis Catheter Drainage Tray, Cardinal Health) are commercially available. You should become familiar with the specific devices available at your institution. You will need the following items: antiseptic solution (chlorhexidine or povidone-iodine), sterile gauze, a sterile drape, sterile gloves, a small syringe for anesthetic injection, 25- and 22-gauge needles for anesthetic injection, and local anesthetic (e.g., lidocaine).

You will also need the following items on hand: an 18-gauge over-the-needle catheter, a large syringe (35 to 60 ml) for the aspiration of pleural fluid, a three-way stopcock, high-pressure drainage tubing, sterile occlusive dressing, specimen tubes, and one or two large evacuated containers. In this video, we use a standard intravenous over-the-needle catheter and other equipment that is commonly available.

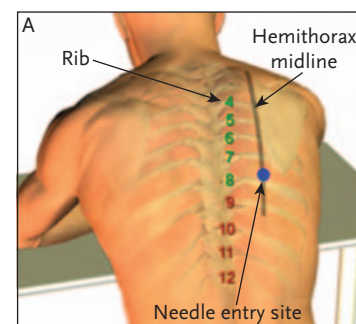
#### PREPARATION

Explain the procedure to the patient, and obtain written informed consent. You should also complete the three preparatory steps outlined by the Universal Protocol of the Joint Commission on Accreditation of Healthcare Organizations: verify the patient's identity, ensure that the needle-insertion site is correctly marked, and take a time-out immediately before the procedure for final verification by all members of the care team that the patient, the procedure, and the site are all correct. (More information is available at <http://www.jointcommission.org/patientsafety/universalprotocol>.)

Thoracentesis is a sterile procedure, and you should wash your hands before the procedure and wear sterile gloves during the procedure. Enlist the help of one or two assistants. They will be needed to help position and monitor the patient and fill the evacuated container and specimen tubes.

Place the patient in a sitting position on the edge of the bed, leaning forward, with his or her arms resting on a bedside table. If the patient is unable to sit upright, the lateral recumbent or supine position may be used. The level of the effusion should be estimated on the basis of diminished or absent sounds on auscultation, dullness to percussion, and decreased or absent fremitus. You should insert the needle one or two intercostal spaces below the level of the effusion, 5 to 10 cm lateral to the spine. To avoid intraabdominal injury, do not insert the needle below the ninth rib. Mark the appropriate site, and then prepare the skin with antiseptic solution and apply a sterile drape.

Anesthetize the epidermis overlying the superior edge of the rib that lies below the selected intercostal space, using 1% or 2% lidocaine and a small (25-gauge) needle. Insert a larger (22-gauge) needle and then “walk” it along the superior edge



**Positioning of the patient and anatomical landmarks**

of the rib, alternately injecting anesthetic and pulling back on the plunger every 2 or 3 mm to rule out intravascular placement and to check for proper intrapleural placement. To avoid injury to the intercostal nerve and vessels, the needle must not touch the inferior surface of the rib. Once pleural fluid is aspirated, stop advancing the needle and inject additional lidocaine to anesthetize the highly sensitive parietal pleura. Note the depth of penetration before withdrawing the needle.

#### ASPIRATION OF PLEURAL FLUID

Attach an 18-gauge over-the-needle catheter to a syringe, and advance the needle along the superior surface of the rib to the predetermined depth while continuously pulling back on the plunger. Once pleural fluid is obtained, stop advancing the needle, carefully guide the catheter over the needle, and then remove the needle. You must cover the open hub of the catheter with a finger to prevent the entry of air into the pleural cavity.

Attach a large syringe with a three-way stopcock to the catheter hub. With the stopcock open to the patient and the syringe, aspirate approximately 50 ml of pleural fluid for diagnostic analysis and then close the stopcock to the patient. If additional fluid is to be removed for therapeutic purposes, one end of high-pressure drainage tubing can be attached to the third port of the stopcock and the other end to a large evacuated container. The stopcock should then be opened to the patient and the container, and the fluid should be allowed to drain. No more than 1500 ml of fluid should be removed.

When the procedure has been completed, remove the catheter while the patient holds his or her breath at end expiration, cover the site with an occlusive dressing, and remove any remaining antiseptic solution from the skin. Make sure that all needles are placed in appropriate safety containers.

#### ANALYSIS OF PLEURAL FLUID

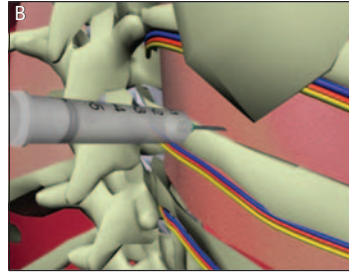
Aspirated fluid should immediately be placed in appropriate specimen tubes and analyzed without delay. A tube without additives should be submitted for the measurement of protein and lactate dehydrogenase levels. The comparison of these values with those for serum protein and lactate dehydrogenase obtained at about the same time will allow a transudate to be distinguished from an exudate (Table 1). If the effusion is a transudate, usually no further evaluation is required and the underlying medical condition should be treated (Table 1).

Additional tubes and a heparinized syringe on ice (for pH determination) will be required for additional testing if the effusion is found to be exudative (Table 2).<sup>1</sup>

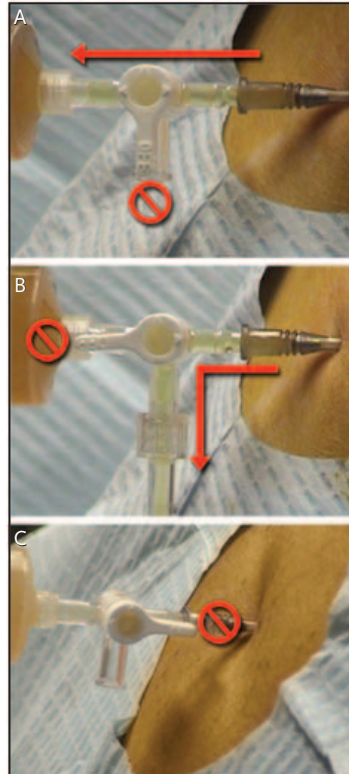
#### COMPLICATIONS

Pneumothorax is rare after thoracentesis and, when present, seldom requires the placement of a chest tube.<sup>3</sup> Although chest radiographs are commonly obtained after thoracentesis, they are not required after simple, uncomplicated procedures. Radiography of the chest should be performed if air was aspirated during the procedure; if chest pain, dyspnea, or hypoxemia develops; if multiple needle passes were required; or if the patient is critically ill or receiving mechanical ventilation.<sup>4</sup>

Other complications of thoracentesis include pain, coughing, and localized infection. More serious complications include hemothorax, intraabdominal-organ injury, air embolism, and postexpansion pulmonary edema. Postexpansion pulmonary edema is rare and can probably be avoided by limiting therapeutic aspirations to less than 1500 ml.<sup>5</sup>



Placement of the needle to avoid intercostal vessels and nerves



Proper use of the three-way stopcock

**Table 2. Additional Tests for the Evaluation of Exudative Effusions.\***

Test	Submission Method	Comments
Cell count and differential count	EDTA-treated tube	Polymorphonuclear-cell predominance suggestive of acute process, such as parapneumonic effusion or pulmonary embolism; mononuclear-cell predominance suggestive of chronic process, such as cancer or tuberculosis
Gram's stain and culture	Syringe for Gram's stain; culture bottles for culture	Consider use of special stains or cultures in specific scenarios (e.g., acid-fast bacilli smear and culture for lymphocytic-predominant exudative effusions)
Hematocrit	EDTA-treated tube	Value 1–20% of serum value suggestive of cancer, pulmonary embolus, or trauma; value >50% of serum value suggestive of hemothorax
Glucose measurement	Tube without additives	Level <60 mg/dl (3.3 mmol/liter) suggestive of parapneumonic effusion or cancer and possibly tuberculosis, rheumatoid arthritis, systemic lupus erythematosus, or esophageal rupture
Cytologic profile	Syringe or evacuated container	Yield increased if cell block, in addition to a simple smear, evaluated
pH	Heparinized syringe (e.g., arterial blood gas syringe) on ice	Chest tube or pleural catheter required to drain parapneumonic effusions with pH <7.2
Triglyceride measurement	Varies†	Level >110 mg/dl (1.2 mmol/liter) suggestive of chylothorax
Amylase measurement	Varies†	Elevated level suggestive of pancreatic disease or esophageal rupture

\* Data are from Light.<sup>1</sup>

† Check with your laboratory.

To avoid complications, follow these six directions. First, make sure you fully understand the equipment you are using, especially if you are using a prepackaged thoracentesis tray with specialized devices. Improper use of the three-way stopcock may lead to pneumothorax. Second, firmly establish the level of the effusion by conducting a careful physical examination. Lateral decubitus radiography is useful in determining whether the effusion is “free-flowing” (i.e., not loculated). Small or loculated effusions are best approached by an experienced operator with ultrasonographic guidance. Third, check for coagulopathy or thrombocytopenia before performing thoracentesis. Fourth, always advance the needle along the superior surface of the rib, to avoid intercostal vessel injury. Fifth, limit therapeutic drainage to less than 1500 ml, to avoid postexpansion pulmonary edema. Sixth, always remove the needle while the patient is at end expiration. Negative intrathoracic pressure during inspiration may lead to pneumothorax.

No potential conflict of interest relevant to this article was reported.

#### REFERENCES

1. Light RW. Pleural effusion. *N Engl J Med* 2002;346:1971-7.
2. McVay PA, Toy PTCY. Lack of increased bleeding after paracentesis and thoracentesis in patients with mild coagulation abnormalities. *Transfusion* 1991;31:164-71.
3. Colt HG, Brewer N, Barbur E. Evaluation of patient-related and procedure-related factors contributing to pneumothorax following thoracentesis. *Chest* 1999;116:134-8.
4. Petersen WG, Zimmerman R. Limited utility of chest radiograph after thoracentesis. *Chest* 2000;117:1038-42.
5. Trachiotis GD, Vricella LA, Aaron BL, Hix WR. As originally published in 1988: reexpansion pulmonary edema. *Ann Thorac Surg* 1997;63:1206-7.

Copyright © 2006 Massachusetts Medical Society.