

VIDEOS IN CLINICAL MEDICINE

Lumbar Puncture

Miles S. Ellenby, M.D., Ken Tegtmeyer, M.D., Susanna Lai, M.P.H.,
and Dana A.V. Braner, M.D.

From the Department of Pediatrics, Division of Pediatric Critical Care, Doernbecher Children's Hospital, Oregon Health and Science University, Portland. Address reprint requests to Dr. Tegtmeyer at the Department of Pediatrics, Division of Pediatric Critical Care, Doernbecher Children's Hospital, Oregon Health and Science University, Mail Code CDRC-P, 707 SW Gaines St., Portland, OR 97239-2901, or at tegtmeye@ohsu.edu.

N Engl J Med 2006;355:e12.
Copyright © 2006 Massachusetts Medical Society.

Lumbar puncture is indicated for both diagnostic and therapeutic reasons. Knowledge of the contraindications, the pertinent anatomy, and the methods to minimize the risk of complications are necessary for the safe and efficient performance of the procedure. Risks, although rare, can be substantial and even potentially life-threatening. The risks can be minimized with an appropriate understanding of the indications, contraindications, and procedural techniques.

INDICATIONS

Lumbar puncture is used to obtain a sample of cerebrospinal fluid (CSF) to aid in the diagnosis of infectious, inflammatory, oncologic, and metabolic processes (Table 1). Therapeutic indications include the delivery of chemotherapy, antibiotics, and anesthetic agents.

Table 1. Indications and Uses for Lumbar Puncture.

Variable	Tests performed on CSF
Diagnostic indications	
Infectious disease	Cell count, differential count, measurement of glucose and protein, cultures
Viral, bacterial, or fungal meningitis	
Encephalitis	
Inflammatory process	Measurement of myelin basic proteins, cell counts, cultures
Multiple sclerosis	
Guillain-Barré syndrome	
Variety of oncologic procedures	Cell counts, smear on cell concentrate
Variety of metabolic processes	Measurement of lactate, pyruvate, glucose, protein
Therapeutic indications	
Numerous procedures requiring lower-body analgesia	
Anesthesia	
Narcotics	
Bupivacaine	
Ventriculitis and some types of meningitis	
Antibiotic administration	
Vancomycin	
Gentamicin	
Some leukemias and lymphomas	
Chemotherapy	
Methotrexate	

CONTRAINDICATIONS

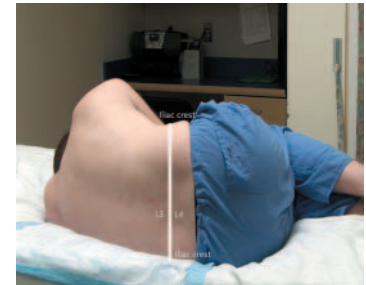
Cardiorespiratory compromise may occur because of the position patients must assume to undergo lumbar puncture; patients with some degree of cardiorespiratory compromise should avoid lumbar puncture.¹ The procedure should also be avoided in patients with signs of cerebral herniation, patients with incipient herniation from increased intracranial pressure, and those with potentially increased intracranial pressure and focal neurologic signs. If there are concerns, cranial computed tomography (CT) should be performed before lumbar puncture, with the caveat that CT may not definitively reveal signs of increased intracranial pressure.² Coagulopathy will increase the risk of a spinal hematoma, although the level of coagulopathy that increases risk is unclear. For patients who have previously undergone lumbar surgery, the likelihood of successful lumbar puncture may be increased if the procedure is performed by an interventional radiologist using imaging techniques.

EQUIPMENT

Commercially available trays contain the necessary supplies, including a spinal needle with a stylet, skin-cleansing agents, drapes, collection tubes, and a manometer. A 22-gauge needle is preferred, because the smaller hole will decrease the risk of CSF leakage. In general, a needle measuring 1.5 in. (3.8 cm) is used in infants, 2.5 in. (6.3 cm) in children, and 3.5 in. (8.9 cm) in adults.

POSITIONING

The patient should assume either the lateral recumbent position or a sitting position. The lateral recumbent position is preferred, to obtain an accurate opening pressure and to reduce the risk of post-puncture headache. Since not all patients can be put in any position, it is reasonable to learn to perform the procedure in both left and right decubitus, as well as the upright, position. Once situated, the patient should be instructed to adopt the fetal position or arch “like a cat” with his or her back flexed, to widen the gap between the spinous processes. The lumbar spine should be perpendicular to the table with the patient in the sitting position and parallel to the table with the patient in the lateral recumbent position.



Proper positioning of the patient

LANDMARKS

Draw a line visually between the superior aspects of the iliac crests that intersects the midline at the L4 spinous process. Insert the needle in the interspace between L3 and L4 or L4 and L5, because these points are below the termination of the spinal cord. You should palpate the landmarks before preparing the skin and applying local anesthesia, since these procedures may obscure the landmarks. Use a skin-marking pen to indicate the proper position.

PREPARATION

After donning sterile gloves, clean the overlying skin with an appropriate disinfectant, either povidone-iodine or a chlorhexidine-based solution. Apply the disinfectant in widening concentric circles. Cover the area with sterile drapes.

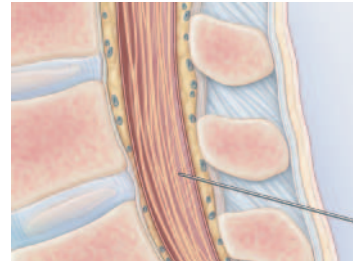
ANALGESIA AND SEDATION

Lumbar puncture is a painful and anxiety-provoking procedure. At a minimum, local anesthesia is appropriate. If time allows, you can apply anesthetic cream topically before preparing the skin. After the skin has been clean and draped, local anesthetic can be infiltrated subcutaneously. Systemic sedatives and analgesics may also be used.

LUMBAR PUNCTURE

After once again palpating the landmarks, insert the needle, with stylet firmly in place, at the superior aspect of the inferior spinous process, in the midline, approximately 15 degrees cephalad, as if aiming at the patient's umbilicus. Recent data suggest that the use of a "pencil-tipped" needle can decrease the risk of postdural puncture headache³ owing to CSF leakage by spreading rather than cutting the fibers of the dural sac. If the more commonly used bevel needle is used, the bevel of the needle should be in the sagittal plane, so as to spread rather than cut the fibers of the dural sac, which run parallel to the spinal axis.

If properly positioned, the needle should pass through, in order, the skin, subcutaneous tissue, supraspinous ligament, interspinous ligament between the spinous processes, ligamentum flavum, epidural space including the internal vertebral venous plexus, dura, and arachnoid, into the subarachnoid space and between the nerve roots of the cauda equina. As the needle passes through the ligamentum flavum, you may feel a popping sensation. After this point, withdraw the stylet in 2-mm intervals to assess for CSF flow.⁴ If the attempt is unsuccessful and bone is encountered, withdraw the needle to the subcutaneous tissue, without exiting the skin, and redirect the needle. CSF will flow once the subarachnoid space has been entered. If the tap was traumatic, the CSF may be tinged with blood. The blood should clear as additional CSF is collected, unless the source of the blood is a subarachnoid hemorrhage. If flow is poor, you may rotate the needle 90 degrees, since a nerve root may be obstructing the opening.



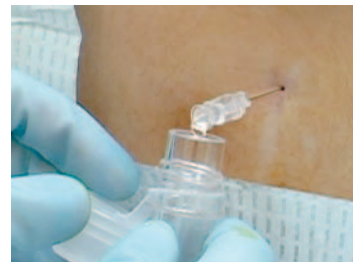Correct angle of the needle

OPENING PRESSURE

An opening pressure can be obtained only from patients in the lateral recumbent position. Use a flexible tube to connect a manometer to the hub of the needle. This should be done before you obtain any samples. A measurement can be made after the column of fluid stops rising. It may be possible to see pulsations from cardiac or respiratory motion.

SPECIMEN COLLECTION

CSF will drip into the collection tubes; it should never be aspirated because even a small amount of negative pressure can precipitate a hemorrhage. The amount of fluid collected should be limited to the smallest volume necessary — typically, 3 to 4 ml. Fluid should be collected from the manometer if an opening pressure was measured by turning the stopcock toward the patient and draining the fluid into a tube. After collecting an adequate specimen, replace the stylet and remove the needle.



Collection of CSF

FOLLOW-UP

The site should be cleaned, and a bandage applied. Despite the widely held belief, bed rest does not decrease the incidence of headaches after lumbar puncture.

COMPLICATIONS

Obese patients may represent a challenge because of difficulty in identifying landmarks. Osteoarthritis, ankylosing spondylitis, kyphoscoliosis, previous lumbar surgery, and degenerative disk disease may make the procedure more difficult. In patients with such conditions, consultation with an anesthesiologist or interventional radiologist may be necessary for lumbar puncture to be successful.

Complications from lumbar puncture include herniation, cardiorespiratory compromise, local or referred pain, headache, bleeding, infection, subarachnoid epider-

mal cyst, and leakage of CSF. The most common complication is headache, occurring in up to 36.5% of patients within 48 hours after the procedure. Headaches can be caused by the leakage of CSF through the puncture site at a rate that exceeds the rate of CSF production. The incidence increases in relation to the size of the spinal needle.⁵ The most serious complication is herniation, which may result when a large pressure gradient exists between the cranial and lumbar compartments. This gradient can be increased during a lumbar puncture, resulting in brain-stem herniation. Patients at high risk for herniation can be identified by a thorough history-taking and neurologic examination. If there is still concern about the procedure, CT may be helpful, with the caveat that these images may not identify pressure elevations. However, CT is not necessary for all patients, because it could delay diagnosis and treatment. Bleeding is most likely to occur in a patient with a bleeding diathesis. The resulting hemorrhage may cause spinal cord compression. No absolute criteria exist regarding the degree of coagulopathy and the risk of bleeding, so clinical judgment is necessary. Subarachnoid epidermal cysts can develop as a consequence of introducing a skin plug into the subarachnoid space and can be avoided through the use of a needle with a stylet.

REFERENCES

1. Marton KI, Gean AD. The spinal tap: a new look at an old test. *Ann Intern Med* 1986;104:840-8.
2. Riordan FA, Cant AJ. When to do a lumbar puncture. *Arch Dis Child* 2002;87:235-7.
3. Strupp M, Schueler O, Straube A, Von Stuckrad-Barre S, Brandt T. "Atraumatic" Sprotte needle reduces the incidence of post-lumbar puncture headaches. *Neurology* 2001;57:2310-2.
4. Carlson D, DiGiulio GA, Givens TG, et al. Lumbar puncture. In: Fleisher GR, Ludwig S, Henretig F, eds. *Textbook of pediatric emergency medicine*. 5th ed. Baltimore: Lippincott Williams & Wilkins, 2006: 1882-3.
5. Boon JM, Abrahams PH, Meiring JH, Welch T. Lumbar puncture: anatomical review of a clinical skill. *Clin Anat* 2004;17: 544-53.

Copyright © 2006 Massachusetts Medical Society.